Ureter

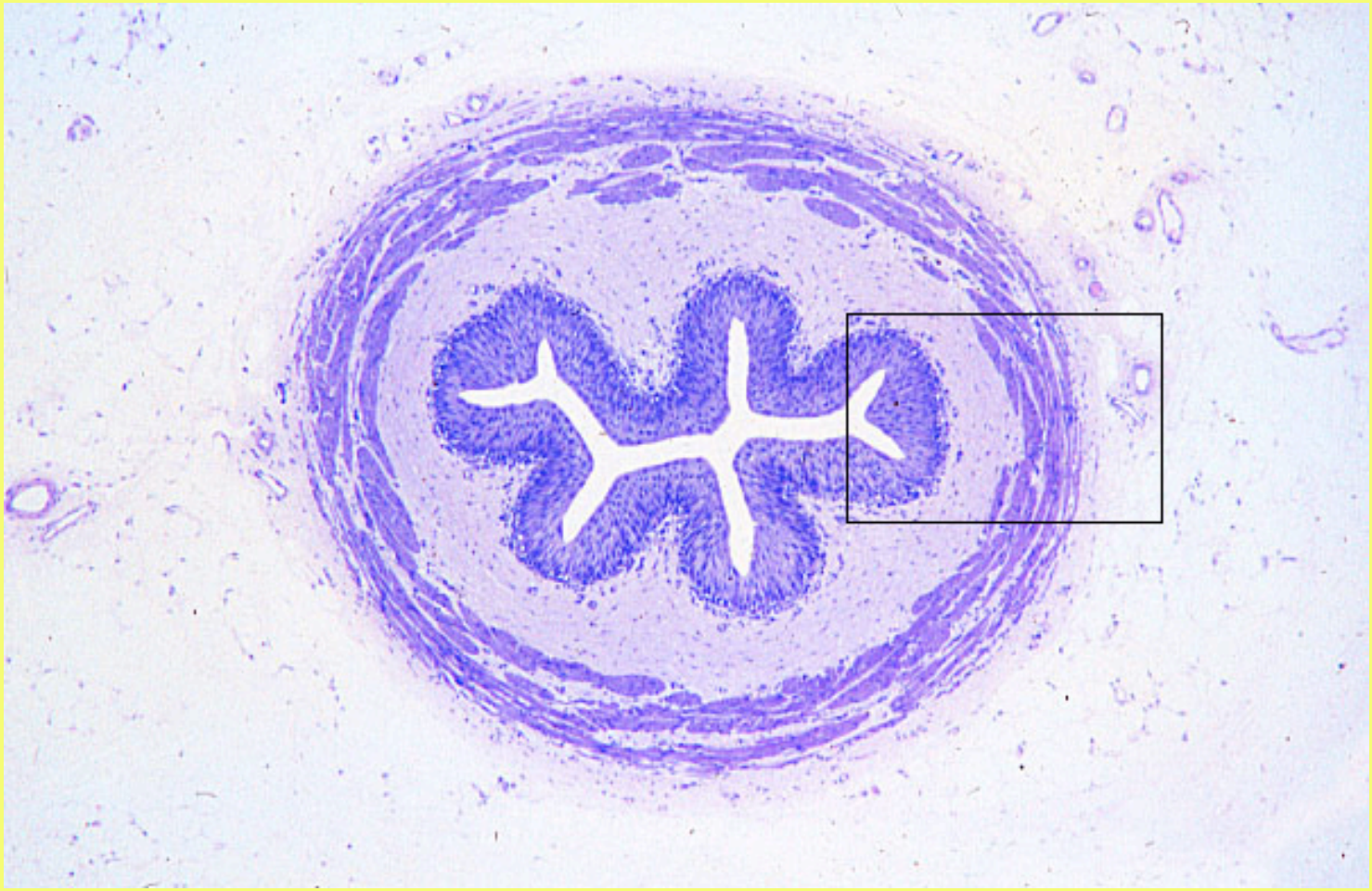

Ureter

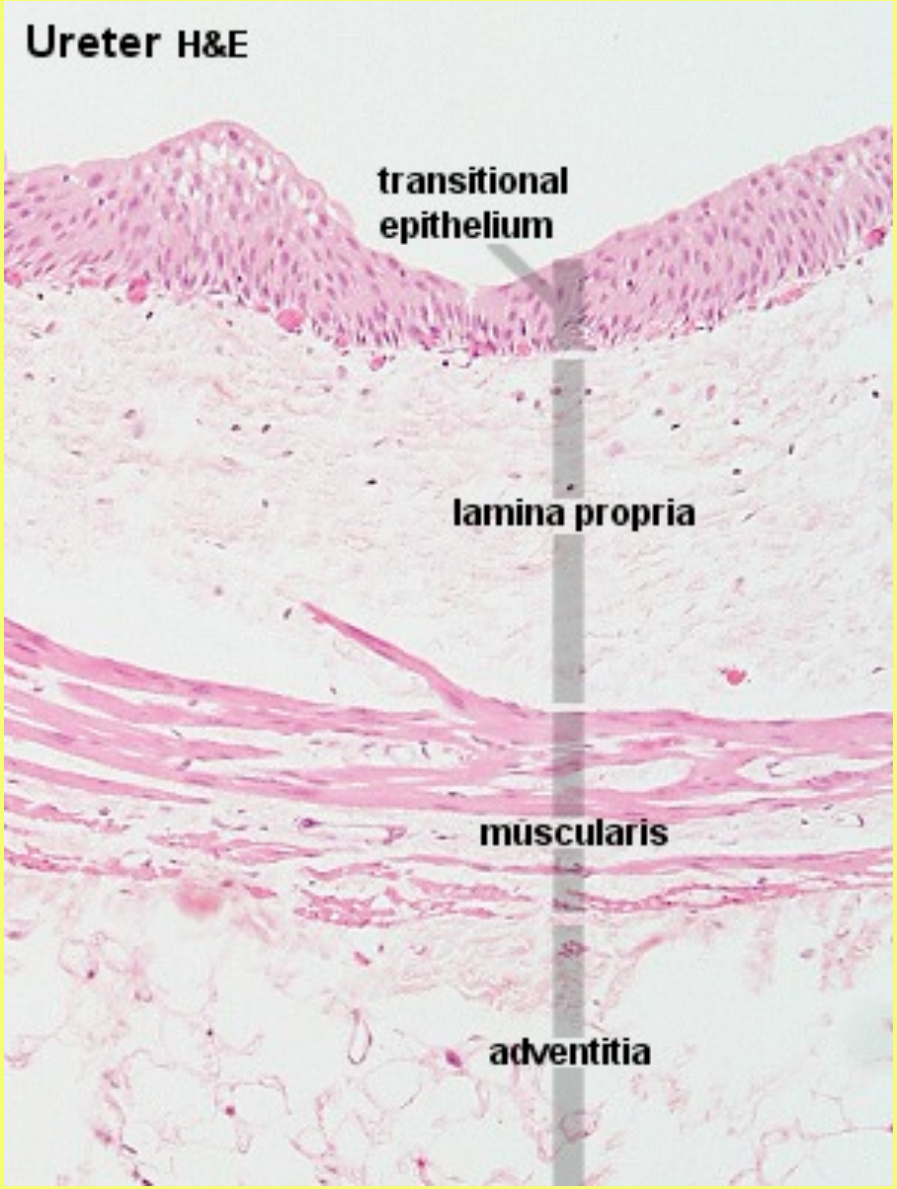
Ureter H&E
transitional
epithelium
lamina propria
muscularis
adventitia

Ureter

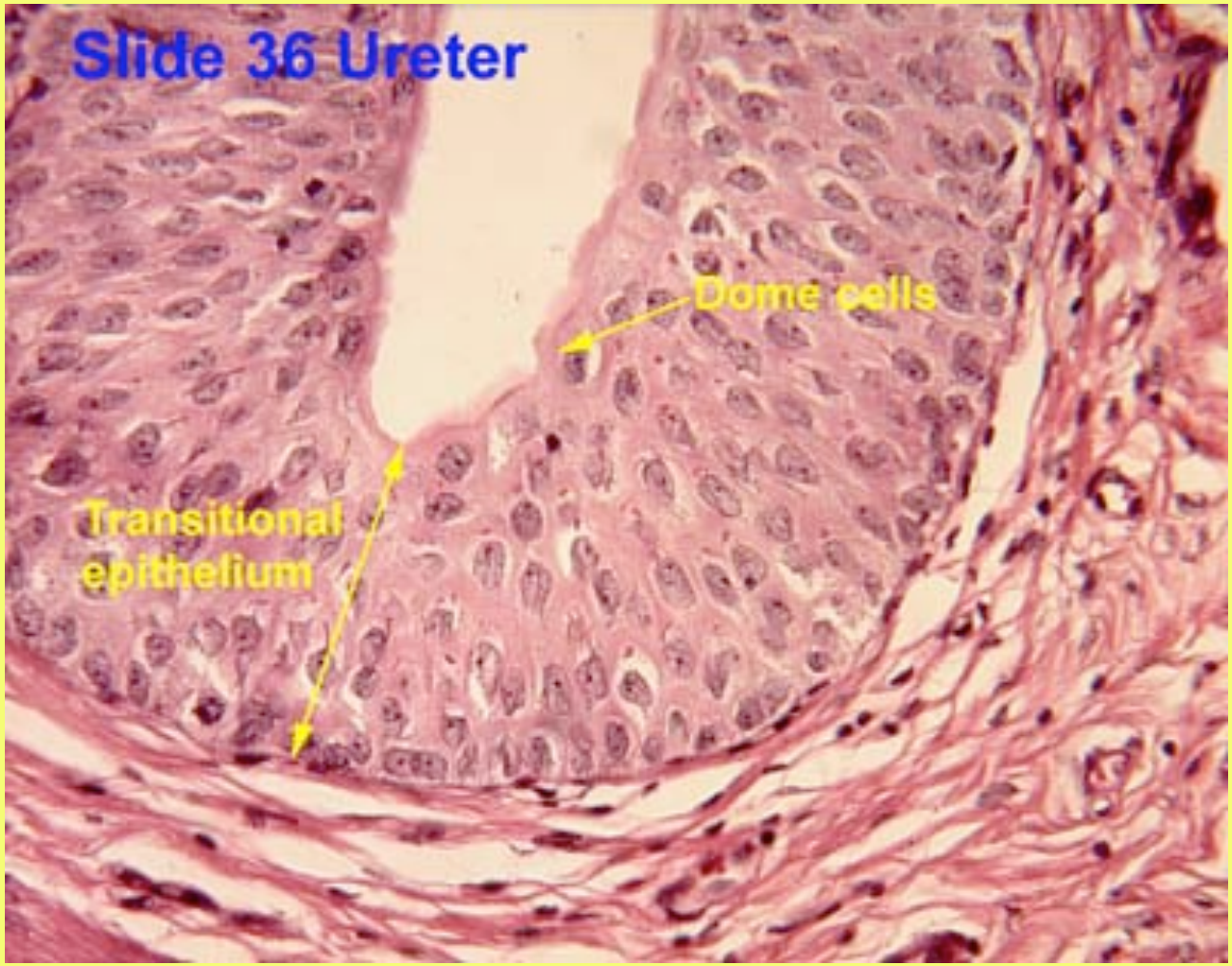

Bladder

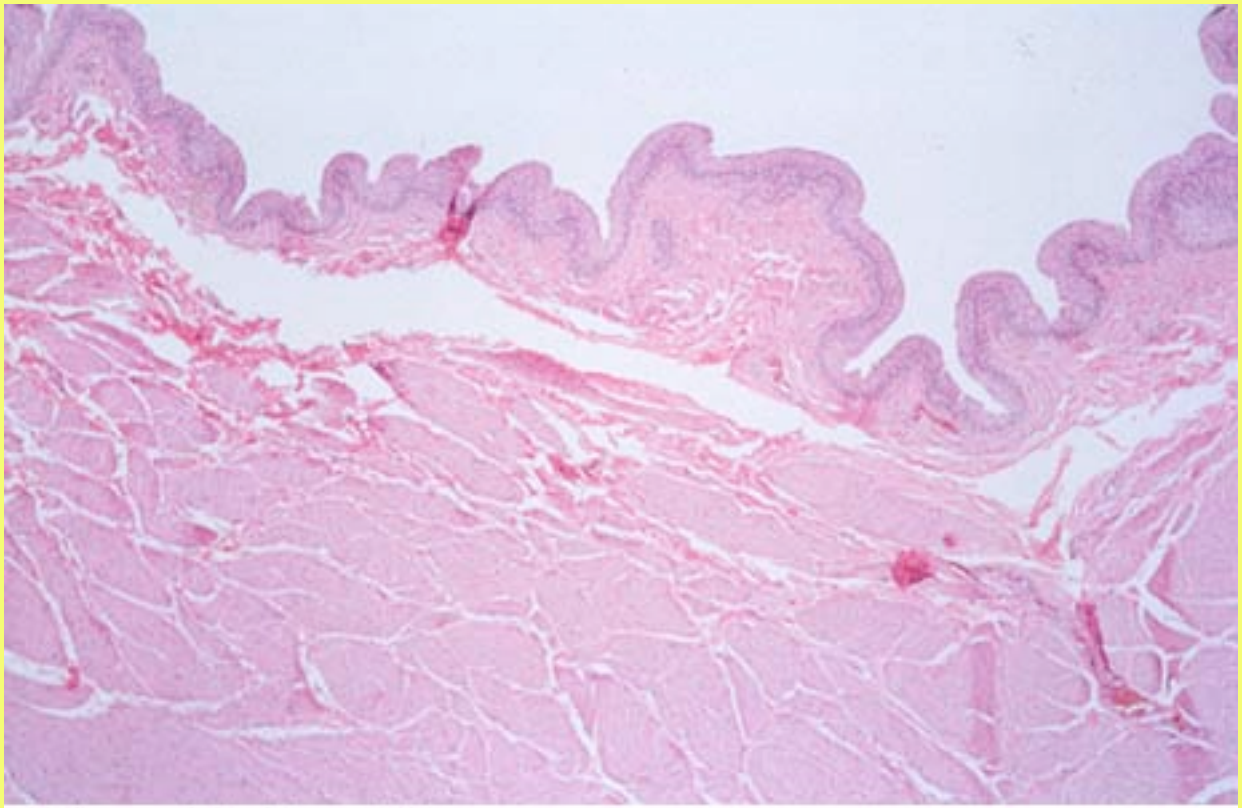

Urinary bladder 40x

Bladder

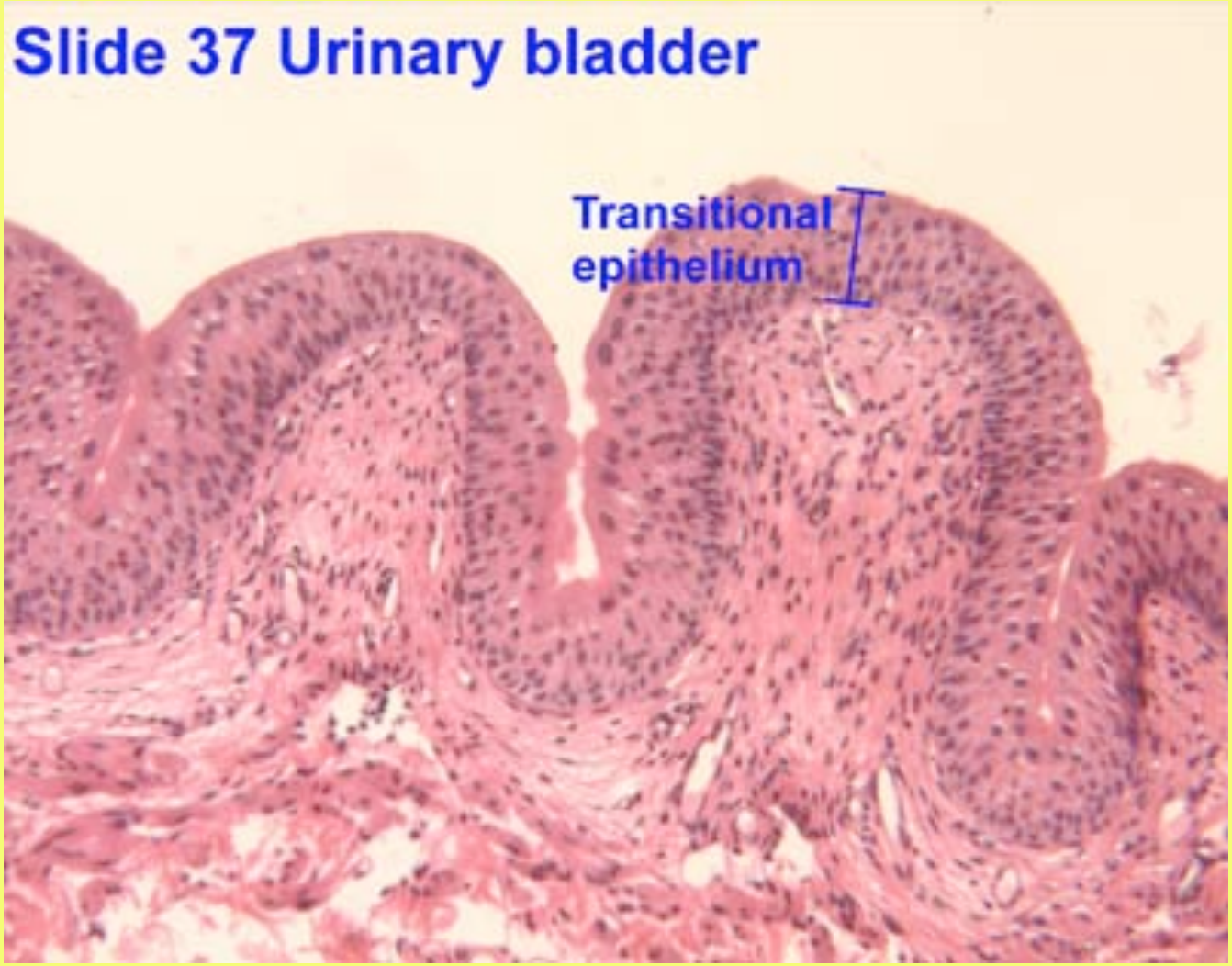

Bladder

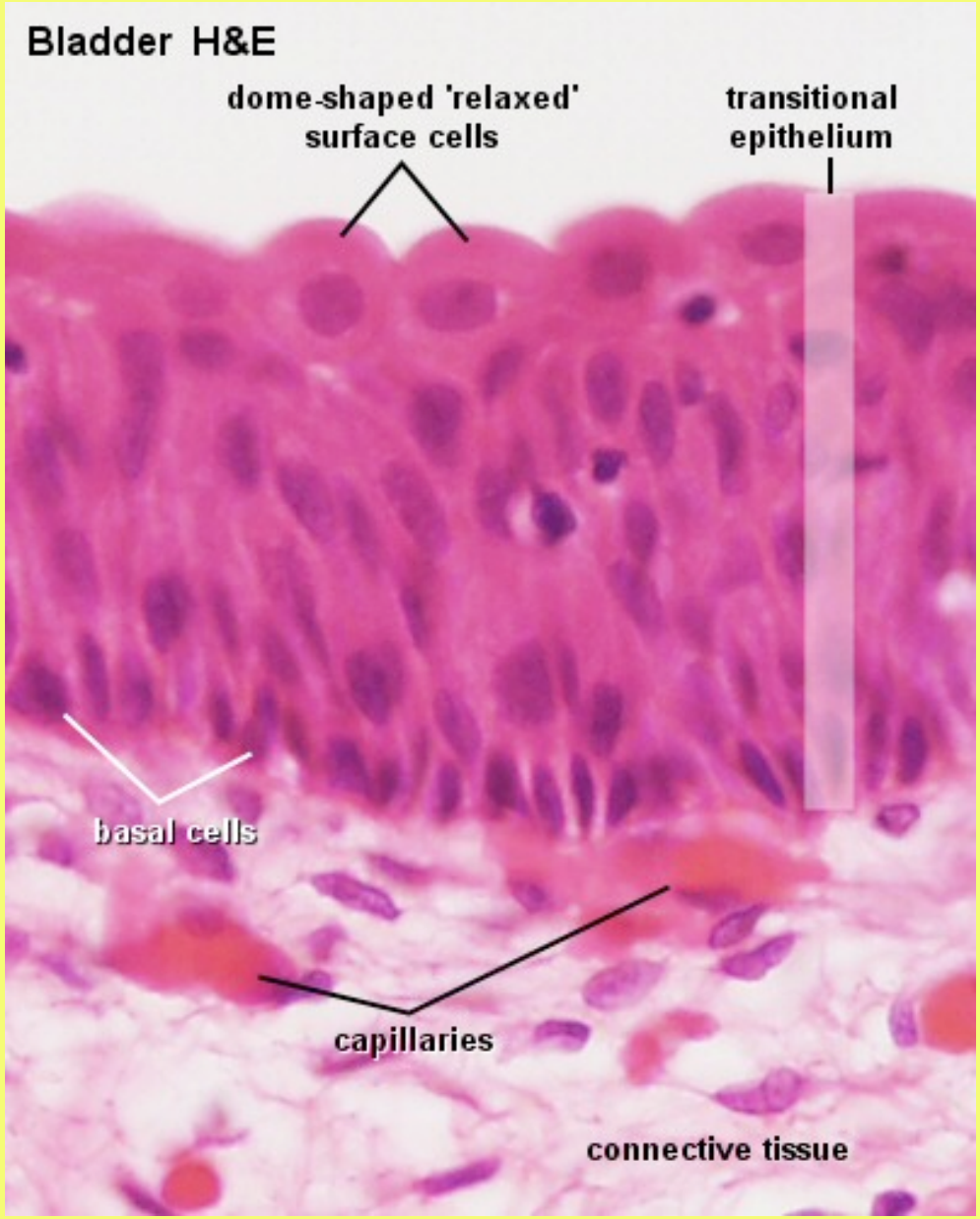
Bladder H&E
dome-shaped 'relaxed' surface cells
transitional epithelium
basal cells
capillaries
connective tissue